

Glenoid Bone Loss in Primary Total Shoulder Arthroplasty: Evaluation and Management

Benjamin W. Sears, MD
Peter S. Johnston, MD
Matthew L. Ramsey, MD
Gerald R. Williams, MD

Abstract

Glenohumeral osteoarthritis is the most common reason for shoulder replacement. Total shoulder arthroplasty provides reliable pain relief and restoration of function, with implant survivorship reported at 85% at 15 years. Glenoid component wear and aseptic loosening are among the most common reasons for revision. Glenoid wear characteristics have been correlated with, among other things, the degree of anatomic glenoid version correction. Anatomic glenoid reconstruction is particularly challenging in the presence of glenoid bone deficiency. Walch classified glenoid morphology into five types: type A, centered, without posterior subluxation but with minor erosion (A1) or major erosion (A2); type B, posteriorly subluxated (B1) or posteriorly subluxated with posterior glenoid erosion (B2); and type C, excessive glenoid retroversion. The type A glenoid represents only 59% of patients; thus, the need to address glenoid deformity is common. Methods of correction include asymmetric reaming of the anterior glenoid, bone grafting of the posterior glenoid, and implanting a specialized glenoid component with posterior augmentation. In many cases of type C or hypoplastic glenoid, the humerus is concentrically reduced in the deficient glenoid and glenoid deformity may not need to be corrected. Severely hypoplastic glenoid may require the use of bone-sparing glenoid components or reverse total shoulder arthroplasty.

The rate of total shoulder arthroplasty (TSA) continues to increase in the United States, with approximately 20,000-25,000 surgeries performed annually and doubling in frequency approximately every 7 years.¹ Osteoarthritis (OA) remains the most common indication for shoulder replacement, and in 95% of these patients, shoulder arthroplasty is associated with pain relief, improved function, and patient satisfaction.² Although implant survivorship is estimated to be >85% at minimum follow-up of 15 years for

most commonly used prostheses,³ a meta-analysis of long-term studies demonstrated the revision burden to be approximately 7%.⁴ Glenoid component failure (ie, aseptic loosening) is the most common complication following shoulder replacement and accounts for most unsatisfactory results.² Factors that contribute to component loosening include altered joint reaction forces, component malposition, and insufficient bony support of the implanted glenoid prosthesis.^{2,4}

Glenoid component malposition-

From Thomas Jefferson University Medical Center, The Rothman Institute, Philadelphia, PA.

J Am Acad Orthop Surg 2012;20:604-613

<http://dx.doi.org/10.5435/JAAOS-20-09-604>

Copyright 2012 by the American Academy of Orthopaedic Surgeons.

ing increases stress forces across the component and is a common reason for failure. In their analysis of 80 successful and 53 failed TSAs, Moskal et al⁵ found no instances of associated glenoid malversion among the successful replacements. However, 46% of the failed TSAs were found to have glenoid component malversion. Shapiro et al⁶ demonstrated that placement of the glenoid in 15° of retroversion significantly decreased the glenohumeral contact area ($P < 0.0002$), increased contact pressures ($P < 0.0002$), and decreased inferior and posterior glenohumeral forces ($P < 0.02$ and $P < 0.03$, respectively), in cadaver specimens. This raises concern for long-term component viability. Farron et al⁷ used finite element analysis to evaluate torque at the cement-bone interface with increasing degrees of glenoid retroversion. They reported an increase in micromotion at the cement-bone interface of >700% and stress increase of 326% with component retroversion >10°. The authors concluded that glenoid retroversion >10° should be corrected and that, if version correction is not possible, the surgeon should consider not performing glenoid resurfacing. Although controversy remains regarding the effect of glenoid malversion on implant longevity, the reported basic science and clinical literature to date support restoration of normal glenoid version as a means of improving component durability.²⁻⁷

Glenoid bone loss has been shown to contribute to glenoid component malpositioning and loosening sec-

ondary to inadequate bone support and incomplete component seating.^{7,8} In addition, the use of asymmetric reaming to manage glenoid bone loss results in reduced amount of bone remaining for fixation, which puts the patient at risk of glenoid vault penetration. Unrecognized cortical penetration can result in cement extrusion. In addition, unless the fixation device (ie, peg, screw, flute, keel) gains purchase of the perforated vault, the initial fixation is likely to be compromised. Uncorrected bone loss may also result in insufficient seating at the periphery of the glenoid component, creating the potential for eccentric loading of the implant and increased stress levels at the implant-bone interface.

OA alters glenohumeral biomechanics and modifies the anatomic features of the glenoid. Over time, these changes result in increased peripheral glenoid contact stresses and posterior glenoid bony erosion, leading to increasing glenoid retroversion and posterior decentralization of the humeral head from the socket. These findings are common in glenohumeral OA and are seen in up to 40% of patients with advanced disease.⁹ These anatomic changes add to the technical difficulty of correct glenoid component implantation and affect the longevity of the implant.

In 1999, Walch et al⁹ examined 113 axillary CT scans of arthritic glenoids and developed a classification system based on wear patterns and version (Figure 1). This classification has become the most commonly used to describe glenoid

morphology. Type A glenoid morphology, which was seen in 59% of patients, consisted of a centered humeral head in the socket, with average glenoid retroversion of 11.5°. These patients were subclassified by degree of glenoid erosion, whether minor (A1) or major (A2). Type B, the next most common glenoid morphology, was associated with posterior subluxation of the humeral head and asymmetric joint force distribution. Type B1 morphology is characterized by a narrowed posterior joint space and lack of posterior erosion. Type B2 is characterized by posterior erosion and an associated biconcave appearance (Figure 2). Type C glenoid is hypoplastic, with retroversion >25°.

Types B2 and C demonstrate the most advanced changes in glenoid morphology and are the most difficult to manage. To effectively treat these patients, the surgeon must have a thorough understanding of the degree of anatomic change, including retroversion, degree of bone loss, and amount of humeral head displacement. Advanced diagnostic imaging, notably three-dimensional (3D) reconstruction CT, is an important tool to evaluate glenoid bone stock and version.^{10,11} Surgical management of glenoid retroversion and bone loss depends on severity. The most common method to correct version involves eccentric reaming of the anterior glenoid, or high side, to a more neutral version. However, with significantly increased version or bone loss, this method can result in removal of a substantial amount

Dr. Ramsey or an immediate family member has received royalties from, serves as a paid consultant to or is an employee of, and has received research or institutional support from, Integra (Ascension), and serves as a board member, owner, officer, or committee member of the American Academy of Orthopaedic Surgeons, the Philadelphia Orthopaedic Society, the Rothman Institute, and the Rothman Specialty Hospital. Dr. Williams or an immediate family member has received royalties from, is a member of a speakers' bureau or has made paid presentations on behalf of, and serves as a paid consultant to or is an employee of, DePuy; has received research or institutional support from Tornier; has stock or stock options held in InVivo Therapeutics; and serves as a board member, owner, officer, or committee member of the American Shoulder and Elbow Surgeons and the Pennsylvania Orthopaedic Society. Neither of the following authors nor any immediate family member has received anything of value from or has stock or stock options held in a commercial company or institution related directly or indirectly to the subject of this article: Dr. Sears and Dr. Johnston.

Figure 1

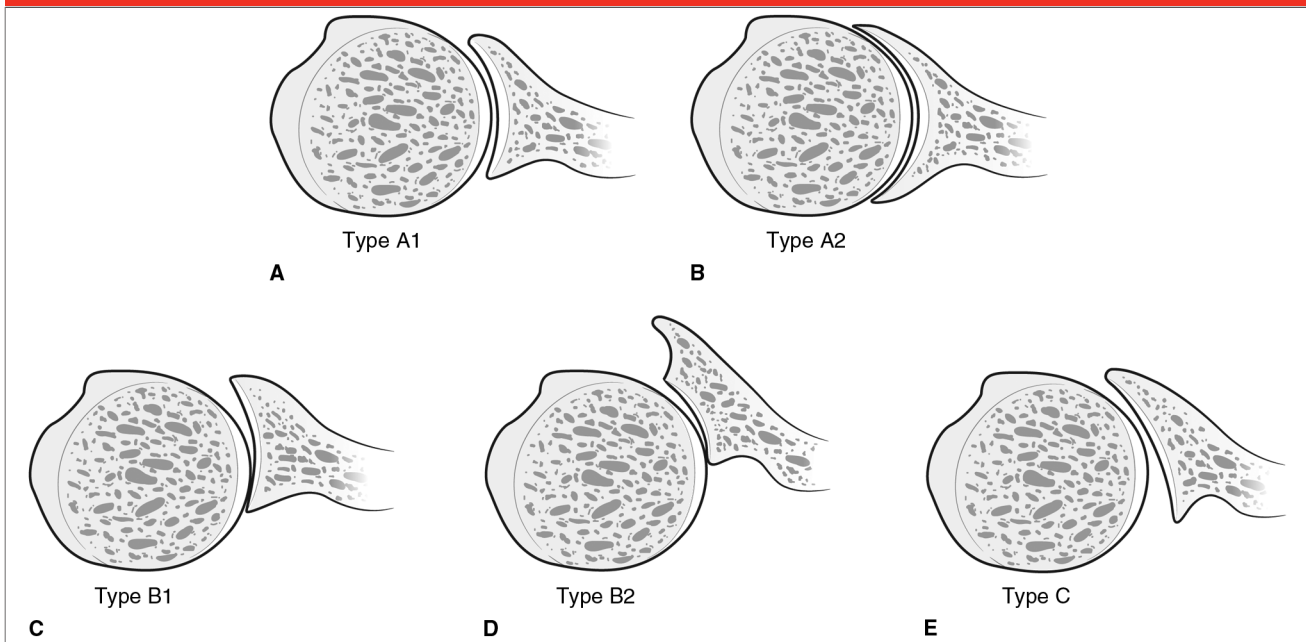


Illustration of the Walch classification of glenoid morphology, which is based on wear patterns and version. **A**, Type A1, centered humeral head with minor glenoid erosion. **B**, Type A2, centered humeral head with major glenoid erosion. **C**, Type B1, posterior subluxation with no erosion. **D**, Type B2, posterior erosion with a biconcave glenoid. **E**, Type C, severe retroversion.

of bone. In these cases, either bone grafting or use of an augmented component may be required. Recognition and management of altered glenoid morphology and diminished bone stock are important for successful shoulder arthroplasty.

Preoperative Evaluation

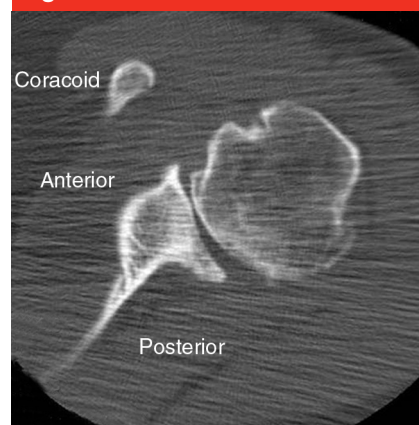
Preoperative planning is essential to manage bone deficiencies and deformity correction in TSA. Although plain radiographs continue to be the standard diagnostic modality, multi-axial 3D imaging has enhanced the interpretation of bony architectural changes associated with shoulder OA. In patients with posterior erosion, CT provides the most definitive evaluation of glenoid version, vault anatomy, and severity of bone loss.¹⁰⁻¹³ This assessment is helpful in determining whether the use of a standard glenoid prosthesis is feasi-

ble or glenoid augmentation is required.

Standard radiographs are necessary for preoperative planning. AP, transscapular lateral, and axillary lateral views should be obtained. The AP radiograph, which is often performed in internal and external rotation, is used to assess bone quality, note the presence of osteophytes, and determine the diameter of the humeral canal. The axillary view provides information on posterior glenoid wear and subluxation. However, the axillary view has been shown to overestimate retroversion in up to 86% of patients.¹²

Early descriptions used CT scans to accurately characterize the anatomy and version of both nonarthritic and arthritic glenoids.¹²⁻¹⁴ Friedman et al¹³ were the first to use CT to characterize the association between glenoid retroversion and OA. They introduced a method to calculate gle-

Figure 2



CT scan of a type B2 glenoid. Note the biconcave glenoid surface and approximately 50% posterior subluxation of the humeral head.

noid version using the transverse axis of the scapula, defined as a line drawn from the tip of the medial border of the scapula to the midpoint of the glenoid fossa. Randelli and Gambrioli¹⁴ also proposed a

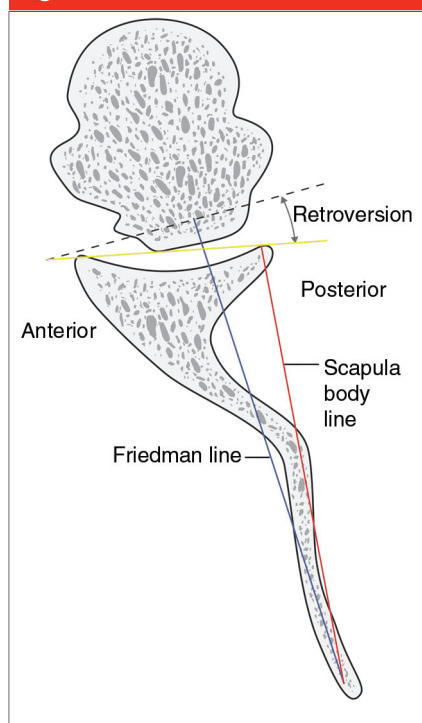
Figure 3

Illustration of the landmarks used to assess glenoid version on CT. A line (ie, Friedman line [blue]) is drawn perpendicular to the axis along the glenoid surface to define neutral version (yellow line). The angle from either the posterior (retroversion) or anterior (anteversion) margins of the glenoid indicates the native version. The black dashed line lies across the face of the glenoid. The red scapula line extends parallel to the scapula body.

technique that uses the scapular body line to calculate glenoid version. In both of these methods, a line drawn perpendicular to the axis along the glenoid surface was defined as neutral version, and the angle from either the posterior margin or the anterior margin of the glenoid defined the native version (retroversion and anteversion, respectively) (Figure 3). More recently, Rouleau et al¹⁵ characterized the glenoid surface with eccentric wear using three new reference lines: the paleoglenoid (original glenoid surface), intermediate glenoid (line from anterior and

posterior edge), and neoglenoid (posterior erosion surface) (Figure 4). These authors determined that the combination of the Friedman method and the intermediate line provide the most reliable determination of glenoid version in the presence of posterior wear. However, although CT is the most accurate modality with which to assess glenoid version, measurements of version have been shown to vary by as much as 10° with only minor changes in scapular rotation in the coronal plane.¹⁶

Recent work has demonstrated the value of 3D CT to accurately characterize glenoid morphology compared with standard two-dimensional CT.^{10,11} Scalise and colleagues^{10,11} have published extensively on the utility of 3D CT in preoperative planning and have developed software to estimate physiologic glenoid version in patients with severe OA and deformity with a glenoid vault model. At our institution, 3D CT is ordered for patients with radiographic evidence of combined glenohumeral subluxation and posterior glenoid erosion. Three-dimensional reconstruction with humeral or scapular subtraction is useful to further characterize bony anatomy in cases of severe deformity and can provide a template to fabricate a reference model for preoperative planning and intraoperative use.

Eccentric Reaming

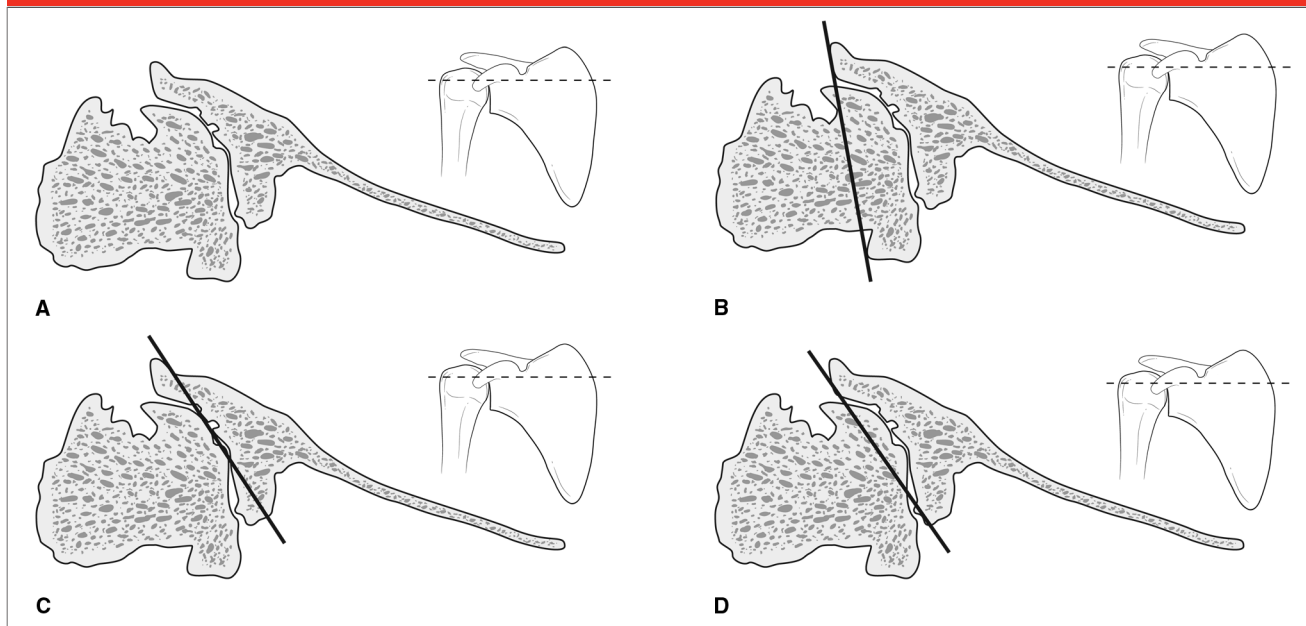
The goals of glenoid resurfacing include correction of version and provision of adequate bone to support the implant. The most common method to correct version involves eccentric reaming of the anterior glenoid to the level of the posterior surface to recreate glenoid version and re-center the humeral head. This technique effectively creates a new

neutral articulation between the glenoid implant and the humeral implant, with the aim of providing congruent contact between the bone and the glenoid prosthesis (Figure 5). Cannulated reaming systems allow placement of a guide pin to assess planned version correction before reaming. These have become popular to help guide reaming in the correct version.

Although eccentric reaming is commonly used to address minor changes in glenoid version, there are no clear guidelines regarding the amount of glenoid erosion that can safely be corrected with this method. Severe retroversion requires the removal of increasing amounts of anterior bone, thereby creating a more severe glenoid deficiency. This can lead to insufficient version correction and placement of the glenoid component in residual retroversion. The importance of version correction was demonstrated by Lazarus et al,¹⁷ who reported that insufficient version correction was the most common cause of poor seating of the glenoid component in their series. Additionally, extensive removal of glenoid bone may jeopardize component stability, leaving inadequate bone stock to support the implant. Removal of bone also effectively medializes the glenohumeral joint line, thereby altering both glenohumeral biomechanics and soft-tissue tensioning. Although humeral lateralization may be improved by increasing the size of the humeral head, the effect of increased humeral component size is unknown.

Several studies have attempted to investigate limits to eccentric reaming for posterior glenoid erosion. Clavert et al¹⁸ eccentrically reamed five cadaver shoulders to create glenoid retroversion of $\geq 15^\circ$ and implanted a four-pegged glenoid component in each. Subsequent CT scans of the shoulders demonstrated peg

Figure 4



Illustrations demonstrating characterization of the glenoid surface with eccentric wear using three new reference lines: Walch type B2 glenoid with posterior erosion (A), paleoglenoid (B), intermediate glenoid (C), and neoglenoid (D). The inset images indicate that the cross section in each panel is at the midportion of the glenoid. (Adapted with permission from Rouleau DM, Kidder JF, Pons-Villanueva J, Dynamidis S, Defranco M, Walch G: Glenoid version: How to measure it? Validity of different methods in two-dimensional computed tomography scans. *J Shoulder Elbow Surg* 2010;19[8]:1230-1237.)

penetration in all specimens which, in theory, limits the cement mantle around each peg and may be a factor in glenoid component loosening. Ultimately, the authors concluded that retroversion $\geq 15^\circ$ cannot be corrected with eccentric reaming. In another cadaver study, Gillespie et al¹⁹ simulated posterior glenoid wear in 5° increments, then eccentrically reamed to neutral and implanted pegged glenoid components. In four of the eight specimens, placement of a glenoid prosthesis was not possible after correction of 15° retroversion secondary to inadequate bone stock and peg penetration. A 20° deformity was not correctable in six specimens. These authors concluded that eccentric reaming to correct posterior wear $>15^\circ$ has only a 50% chance of successful correction by eccentric reaming and that instead, bone grafting should be considered to address this defect.

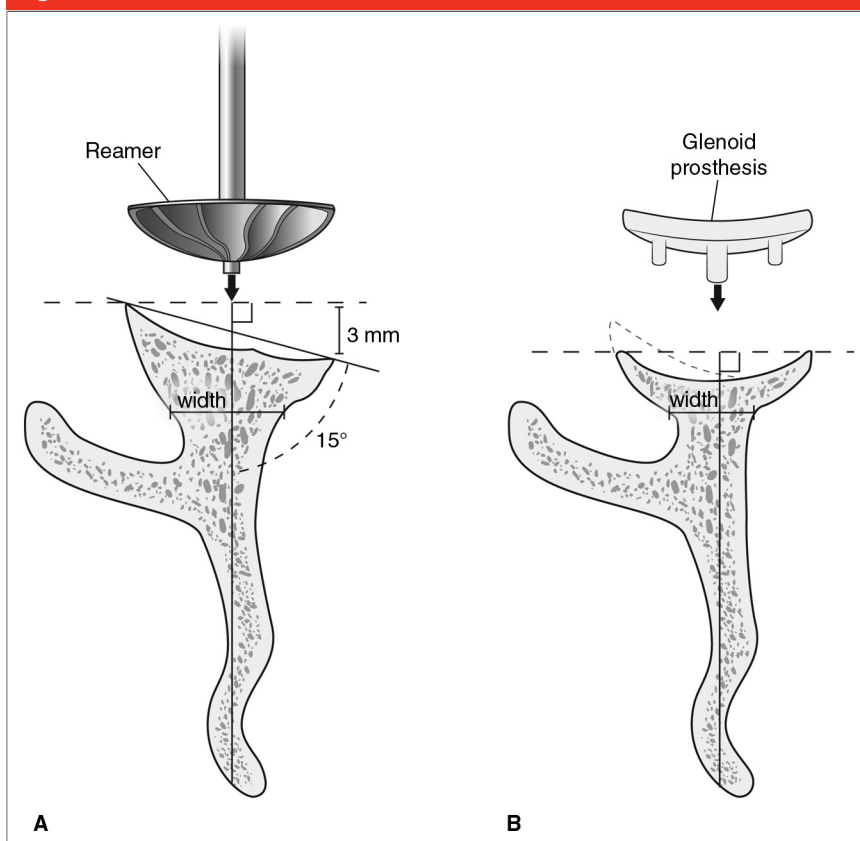
Nowak et al²⁰ used 3D models created from CT scans of patients with advanced glenohumeral OA to simulate asymmetric reaming and resurfacing in varying degrees of glenoid retroversion. They used an in-line three-peg glenoid component as the resurfacing implant. Correction of glenoid retroversion $<12^\circ$ did not result in vault penetration. However, all glenoids with retroversion $>18^\circ$ demonstrated component peg penetration. Ultimately, results from this study demonstrate that advancing degrees of retroversion beyond 12° , and all of those over 18° , may not be amenable to correction by eccentric reaming.

Clinical results of TSA following asymmetric reaming are limited. Habermeyer et al²¹ prospectively studied a cohort of patients undergoing TSA to address posterior glenoid wear. In all cases, the humeral head was maintained in a recentered posi-

tion following surgical correction of glenoid alignment in the transverse plane and soft-tissue balancing. Gerber et al²² reported that eccentric reaming resulted in correction of posterior humeral subluxation in 21 of 23 patients (91%). No correlation was found between the ability to recenter the humeral head and the degree of preoperative glenoid version or correction.

Several cadaver and clinical investigations have demonstrated the effectiveness and safety of computer navigation in improving measurement of version intraoperatively.²³⁻²⁵ Kircher et al²⁴ reported improved version correction using computer navigation in a prospective, randomized clinical trial. Version correction from 15.4° to 3.7° was achieved with navigation, whereas correction without navigation resulted in improvement from 14.4° to only 10.9° . No follow-up outcome data were ob-

Figure 5



Illustrations of eccentric reaming to create a neutral articulation between the bone and glenoid prosthesis. A reamer in the neutral position is used to ream down the high side (A) to create a perpendicular articulating surface that can accept the glenoid implant (B). Although version can be corrected, the glenoid is medialized, and the width of the remaining glenoid bone becomes narrower following the removal of anterior bone.

tained; however, the use of navigation appears to improve glenoid positioning and provides immediate, objective measurements of glenoid version.

Eccentric reaming to correct version is a common and useful surgical option. However, there are limitations to the degree of version that may be appropriately corrected.

Posterior Bone Graft

Bone grafting provides a biologic solution in cases of substantial bone loss that prevents adequate version correction or secure seating of a glenoid component. Indications for

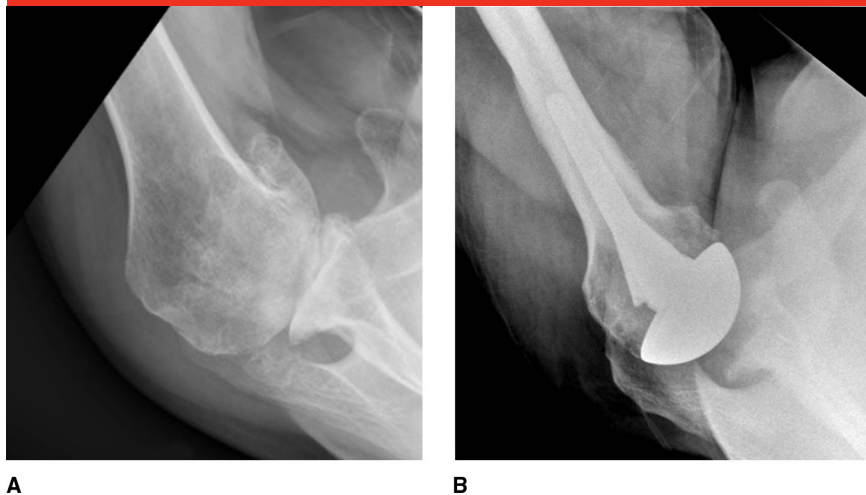
bone grafting include uneven wear that cannot be accommodated by small changes in glenoid or humeral component version, insufficient bone volume to support the glenoid component, $>15^\circ$ of retroversion, and potential penetration of the glenoid vault after version corrections.²⁶⁻²⁸

Advantages of bone grafting in the setting of posterior bone deficiencies include preservation of anterior glenoid bone stock and maintenance of a more normal joint line that avoids altered joint kinematics secondary to shortening of the glenoid vault. Additionally, theoretically, bone grafting provides a permanent restorative solution to glenoid bone loss. Disad-

vantages include graft dissolution, nonunion, fixation failure, and shift leading to settling. Additionally, bone grafting is technically difficult and not reproducible as a result of high variability with graft contouring.

Multiple grafting techniques have been described, with varying results. Three retrospective reviews in the literature have reported the results of bone grafting for eccentric glenoid wear, with incidence rates ranging from 3.3% to 16% of primary shoulder arthroplasties.²⁶⁻²⁸ Neer and Morrison²⁶ reported excellent results in 16 patients and satisfactory results (or attainment of desired limited goals) in 3 patients, and no revision surgeries. No glenoid loosening or migration had occurred at a minimum follow-up of 2 years (average, 4.4 years). Steinmann and Cofield²⁷ reported less favorable results in their series of 28 patients who underwent bone grafting for eccentric wear; however, this study included patients with instability. Fifteen patients (54%) demonstrated some degree of radiographic lucency, and three glenoids were radiographically loose at an average follow-up of 5.3 years (range, 2 to 11 years). Despite these findings, patient satisfaction was similar to that reported by Neer and Morrison.²⁶ In the most recent series, Hill and Norris²⁸ reported on 17 shoulders that required bone grafting secondary to anterior or posterior instability. In this challenging patient population, there were five glenoid failures requiring revision as a result of instability (two patients), one recurrent rotator cuff tear, one improper placement of glenoid component, and one glenoid failure. These complications occurred within 2 to 91 months of the initial surgery. Nine of 17 shoulders were stable after bone grafting (53%), with a similar distribution for functional satisfaction.

Figure 6



A, Preoperative axillary radiograph of a type B2 glennoid demonstrating approximately 7 mm of posterior bone erosion. **B**, Postoperative axillary radiograph following implantation of the Global Steptech APG augmented glennoid component (DePuy, Warsaw, IN) and 7 mm of posterior buildup.

At our institution, bone loss >10 to 15 mm as measured on axial CT scans is an indication for bone grafting. Ideally, the native osteotomized humeral head can be used as a structural graft. There are no current published investigations regarding this technique; however, we have found utilization of the native humeral head to be very useful as it is typically structurally sound and essentially precontoured to match the glennoid defect. The center of the glennoid can be identified with the help of specialized cannulated sizer disks. Using these disks, a centralized guide-wire is drilled perpendicular to the neutral glennoid axis, which allows for version correction through limited reaming of the high side of the glennoid. The deficient side is then lightly prepared with a burr to expose a bleeding surface to receive the bone graft. The graft is contoured to fit the defect and placed with the articular side (ie, subchondral bone) facing the glennoid. The curvatures typically closely match because the native humeral head is accountable for creating the defect. The graft is

temporarily fixed with small Steinmann pins, which are replaced with countersunk 3.5-mm screws positioned to avoid glennoid implant pegs. The graft contour is then further refined with a burr, and the holes are drilled for glennoid implantation. Trial glennoid implantation is essential to ensure secure seating and fit of the glennoid prosthesis to the bone.

Augmented Glennoid Component

New prosthetic solutions to glennoid bone loss have been driven by limitations in other options, such as demonstrated lack of durability and early glennoid failure in patients with eccentric wear.^{29,30} Although augmented components with a fixed polyethylene buildup theoretically may ensure more reliable restoration of the joint line, the mechanical properties of polyethylene in this setting are unknown.

Although the concept of glennoid component augmentation is not new, there is a paucity of data on its effi-

cacy. Neer et al³¹ initially presented an augmented glennoid component consisting of a sloped posterior buildup. However, description of this device was limited, and we are unaware of any results on its use. Rice et al³⁰ reported on their results using a Cofield 2 keeled all-polyethylene augmented glennoid (Smith & Nephew, Memphis, TN), which was implanted in 14 shoulders with OA and associated posterior glennoid deficiency. This augmented component provided version correction of approximately 4°. Despite satisfactory midterm pain relief and functional outcome, use of this component was discontinued as a result of persistent instability.

Other augmented glennoid components have been recently introduced, such as the Global Steptech APG (DePuy, Warsaw, IN) and the Posterior Augment Glennoid (Exactech, Gainesville, FL). These offer an alternative to asymmetric reaming and bone grafting (Figure 6). The long-term clinical performance of these augmented components has not been evaluated.

Dysplastic Glennoid

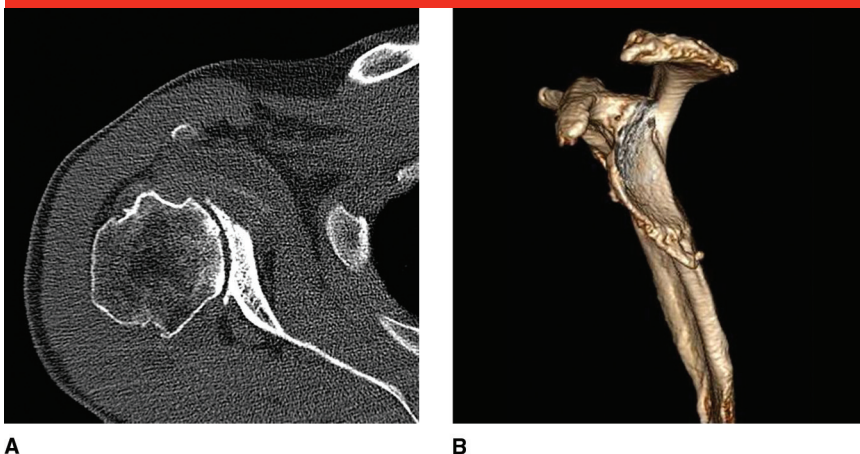
Walch et al⁹ defined type C glennoid morphology as glennoid retroversion of >25° regardless of the degree of erosion. This is most commonly associated with congenital or dysplastic development. Normal glennoid fossa development occurs from proximal and distal ossification centers.³² Incomplete ossification of one or both of these centers may cause underdevelopment of the posterior and inferior cartilaginous glennoid and neck of the scapula.³³ Although glennoid dysplasia is thought to be rare, reports indicate that it may be more common than previously speculated.^{9,34} Edelson³⁴ examined 1,150 scapular bone specimens from sev-

eral museum collections representing several different ethnic populations. He found localized hypoplasia of the posteroinferior glenoid in 20% to 35% of specimens. Even so, a direct link between glenoid dysplasia and secondary development of glenohumeral OA has not been established. Edwards et al³⁵ reported that only 3.5% of patients with primary OA undergoing TSA were found to have glenoid dysplasia.

Although excessive glenoid retroversion is characteristic of the dysplastic shoulder, the humerus and surrounding soft tissues appear to adapt to the glenoid morphology, thereby allowing the humeral head to remain centered in the retroverted socket. That is, even though the center of the humeral head lies posterior to the scapular plane, it is contained within the anterior and posterior confines of the glenoid surface (Figure 7). This important feature distinguishes the hypoplastic glenoid from the biconcave (type B2) glenoid, which is associated with extensive glenoid bone erosion and posterior humeral head subluxation with respect to the glenoid surface. Posterior glenoid erosion was minimal in one series of 15 patients with OA and dysplasia.³⁵ Additionally, these patients had developed posterior soft-tissue hyperplasia that seemingly prevented posterior subluxation. During glenoid preparation, the investigators reamed to the native glenoid (ie, no eccentric reaming) and made no attempt to correct version or augment posterior soft tissue. At our institution, the posterior capsule is also preserved in such cases as a checkrein to posterior displacement of the humeral head.

Although there are limited reports on surgical treatment in symptomatic patients with dysplastic glenoids, shoulder arthroplasty has been shown to be a viable option.^{35,36} Edwards et al³⁵ reported significant im-

Figure 7



Axial CT scan (A) and sagittal three-dimensional CT reconstruction (B) of a dysplastic glenoid. Although this glenoid is in $>35^\circ$ of retroversion, it remains contained within the anterior and posterior confines of the glenoid surface. This finding distinguishes the morphology of the dysplastic glenoid from the type B2 glenoid, in which the humeral head lies subluxated posteriorly and the glenoid has a biconcave appearance.

provement in outcome following arthroplasty, including increased pain relief, motion, and function. In cases of severe dysplasia, the amount of bone available for fixation may be inadequate for standard fixation options. In these patients, the use of an inset bone-sparing glenoid component with a single, short peg may be helpful to avoid cortical penetration.²⁹ Complete correction of version in dysplastic glenoids can result in substantial loss of internal rotation as a result of excessive tensioning of posterior tissues. Unlike the type B2 glenoid, the dysplastic glenoid is associated with minimal posterior subluxation of the humerus and, therefore, the posterior tissues are not excessively lax. Thus, aggressive version correction can place tension on the posterior soft tissues and limit the ability of the humerus to rotate internally. However, partial correction may be attempted to restore native retroversion if the humeral head has eroded into the posterior glenoid. In sedentary persons and elderly persons (aged >70 years),

placement of reverse TSA, which is a more constrained device, may be considered to stabilize the glenohumeral joint.

In cases in which bone erosion or version is too significant to allow placement of a glenoid component, replacement of the humeral head without glenoid resurfacing has been shown to result in acceptable outcomes, even in young patients.³⁷ The criteria used by Edwards et al³⁵ for glenoid resurfacing was ≥ 15 mm of glenoid bone depth on axial CT. These investigators found that patients who underwent hemiarthroplasty still had significant improvements in pain scores and functional measures. A recent investigation by Bonneville et al³⁷ reported marked improvement in pain scores, function, and outcome measures at a minimum 2-year follow-up in nine patients treated with hemiarthroplasty for dysplasia. The authors concluded that hemiarthroplasty is a reliable management option for this patient population. Glenohumeral arthritis secondary to glenoid dyspla-

sia appears to be relatively uncommon, but it may be effectively managed with TSA or hemiarthroplasty with limited correction of the natural version of the glenoid.

Summary

Advanced glenohumeral OA is associated with increased glenoid retroversion, posterior erosion, and glenoid bone loss. Surgical resurfacing of the glenoid requires correction of these anatomic alterations to allow placement of the implant in near-neutral version with adequate bony structural support. This is done in an effort to avoid early failure of the replacement. Selection of surgical technique depends on the severity of deformity and the degree of bone loss. Typically, minor changes in version and limited bone loss can be adequately corrected with eccentric reaming of the glenoid to neutral or near-neutral version. However, extensive glenoid bone loss may require augmentation with either bone graft or specialized glenoid implants to restore version and support glenoid component implantation. Extensive bone loss may make glenoid resurfacing impossible.

Glenoid bone loss is a challenging problem that is commonly encountered with the osteoarthritic glenoid. Appropriate assessment and correction are critical for long-term outcomes following TSA. Further research is necessary to determine the most effective approach to glenoid management in these difficult cases.

References

Evidence-based Medicine: Levels of evidence are listed in the table of contents. In this article, references 2, 8, 9, 17, and 24 are level II studies. References 1, 4, 5, 12, 13, 21, 23, 28,

29, and 34 are level III studies. References 3, 22, 26, 27, 30, 32, 33, and 35-37 are level IV studies. Reference 31 is level V expert opinion.

References printed in **bold type** indicate those published within the past 5 years.

- Day JS, Lau E, Ong KL, Williams GR, Ramsey ML, Kurtz SM: Prevalence and projections of total shoulder and elbow arthroplasty in the United States to 2015. *J Shoulder Elbow Surg* 2010; 19(8):1115-1120.
- Norris TR, Iannotti JP: Functional outcome after shoulder arthroplasty for primary osteoarthritis: A multicenter study. *J Shoulder Elbow Surg* 2002; 11(2):130-135.
- Cil A, Veillette CJ, Sanchez-Sotelo J, Sperling JW, Schleck CD, Cofield RH: Survivorship of the humeral component in shoulder arthroplasty. *J Shoulder Elbow Surg* 2010;19(1):143-150.
- Bohsali KI, Wirth MA, Rockwood CA Jr: Complications of total shoulder arthroplasty. *J Bone Joint Surg Am* 2006; 88(10):2279-2292.
- Moskal MJ, Duckworth D, Matsen FA: Abstract: An analysis of 122 failed shoulder arthroplasties. *J Shoulder Elbow Surg* 1999;8:554.
- Shapiro TA, McGarry MH, Gupta R, Lee YS, Lee TQ: Biomechanical effects of glenoid retroversion in total shoulder arthroplasty. *J Shoulder Elbow Surg* 2007;16(3 suppl):S90-S95.
- Farron A, Terrier A, Büchler P: Risks of loosening of a prosthetic glenoid implanted in retroversion. *J Shoulder Elbow Surg* 2006;15(4):521-526.
- Iannotti JP, Norris TR: Influence of preoperative factors on outcome of shoulder arthroplasty for glenohumeral osteoarthritis. *J Bone Joint Surg Am* 2003;85(2):251-258.
- Walch G, Badet R, Boulahia A, Khoury A: Morphologic study of the glenoid in primary glenohumeral osteoarthritis. *J Arthroplasty* 1999;14(6):756-760.
- Scalise JJ, Bryan J, Polster J, Brems JJ, Iannotti JP: Quantitative analysis of glenoid bone loss in osteoarthritis using three-dimensional computed tomography scans. *J Shoulder Elbow Surg* 2008; 17(2):328-335.
- Scalise JJ, Codsí MJ, Bryan J, Brems JJ, Iannotti JP: The influence of three-dimensional computed tomography images of the shoulder in preoperative planning for total shoulder arthroplasty. *J Bone Joint Surg Am* 2008;90(11):2438-2445.
- Nyffeler RW, Jost B, Pfirrmann CW, Gerber C: Measurement of glenoid version: Conventional radiographs versus computed tomography scans. *J Shoulder Elbow Surg* 2003;12(5):493-496.
- Friedman RJ, Hawthorne KB, Genez BM: The use of computerized tomography in the measurement of glenoid version. *J Bone Joint Surg Am* 1992;74(7):1032-1037.
- Randelli M, Gambrioli PL: Glenohumeral osteometry by computed tomography in normal and unstable shoulders. *Clin Orthop Relat Res* 1986; (208):151-156.
- Rouleau DM, Kidder JF, Pons-Villanueva J, Dynamidis S, Defranco M, Walch G: Glenoid version: How to measure it? Validity of different methods in two-dimensional computed tomography scans. *J Shoulder Elbow Surg* 2010;19(8):1230-1237.
- Bokor DJ, O'Sullivan MD, Hazan GJ: Variability of measurement of glenoid version on computed tomography scan. *J Shoulder Elbow Surg* 1999;8(6):595-598.
- Lazarus MD, Jensen KL, Southworth C, Matsen FA III: The radiographic evaluation of keeled and pegged glenoid component insertion. *J Bone Joint Surg Am* 2002;84(7):1174-1182.
- Clavert P, Millett PJ, Warner JJ: Glenoid resurfacing: What are the limits to asymmetric reaming for posterior erosion? *J Shoulder Elbow Surg* 2007; 16(6):843-848.
- Gillespie R, Lyons R, Lazarus M: Eccentric reaming in total shoulder arthroplasty: A cadaveric study. *Orthopedics* 2009;32(1):21.
- Nowak DD, Bahu MJ, Gardner TR, et al: Simulation of surgical glenoid resurfacing using three-dimensional computed tomography of the arthritic glenohumeral joint: The amount of glenoid retroversion that can be corrected. *J Shoulder Elbow Surg* 2009; 18(5):680-688.
- Habermeyer P, Magosch P, Lichtenberg S: Recentering the humeral head for glenoid deficiency in total shoulder arthroplasty. *Clin Orthop Relat Res* 2007;457:124-132.
- Gerber C, Costouros JG, Sukthankar A, Fucentese SF: Static posterior humeral head subluxation and total shoulder arthroplasty. *J Shoulder Elbow Surg* 2009;18(4):505-510.
- Edwards TB, Gartsman GM, O'Connor DP, Sarin VK: Safety and utility of computer-aided shoulder arthroplasty. *J Shoulder Elbow Surg* 2008;17(3):503-508.

24. Kircher J, Wiedemann M, Magosch P, Lichtenberg S, Habermeyer P: Improved accuracy of glenoid positioning in total shoulder arthroplasty with intraoperative navigation: A prospective-randomized clinical study. *J Shoulder Elbow Surg* 2009;18(4):515-520.
25. Nguyen D, Ferreira LM, Brownhill JR, et al: Improved accuracy of computer assisted glenoid implantation in total shoulder arthroplasty: An in-vitro randomized controlled trial. *J Shoulder Elbow Surg* 2009;18(6):907-914.
26. Neer CS II, Morrison DS: Glenoid bone-grafting in total shoulder arthroplasty. *J Bone Joint Surg Am* 1988;70(8):1154-1162.
27. Steinmann SP, Cofield RH: Bone grafting for glenoid deficiency in total shoulder replacement. *J Shoulder Elbow Surg* 2000;9(5):361-367.
28. Hill JM, Norris TR: Long-term results of total shoulder arthroplasty following bone-grafting of the glenoid. *J Bone Joint Surg Am* 2001;83(6):877-883.
29. Gunther SB, Lynch TL: Total shoulder replacement surgery with custom glenoid implants for severe bone deficiency. *J Shoulder Elbow Surg* 2012;21(5):675-684.
30. Rice RS, Sperling JW, Miletti J, Schleck C, Cofield RH: Augmented glenoid component for bone deficiency in shoulder arthroplasty. *Clin Orthop Relat Res* 2008;466(3):579-583.
31. Neer CS II, Watson KC, Stanton FJ: Recent experience in total shoulder replacement. *J Bone Joint Surg Am* 1982;64(3):319-337.
32. Wirth MA, Lyons FR, Rockwood CA Jr: Hypoplasia of the glenoid: A review of sixteen patients. *J Bone Joint Surg Am* 1993;75(8):1175-1184.
33. Currarino G, Sheffield E, Twickler D: Congenital glenoid dysplasia. *Pediatr Radiol* 1998;28(1):30-37.
34. Edelson JG: Localized glenoid hypoplasia: An anatomic variation of possible clinical significance. *Clin Orthop Relat Res* 1995;(321):189-195.
35. Edwards TB, Boulahia A, Kempf JF, Boileau P, Némoz C, Walch G: Shoulder arthroplasty in patients with osteoarthritis and dysplastic glenoid morphology. *J Shoulder Elbow Surg* 2004;13(1):1-4.
36. Sperling JW, Cofield RH, Steinmann SP: Shoulder arthroplasty for osteoarthritis secondary to glenoid dysplasia. *J Bone Joint Surg Am* 2002;84(4):541-546.
37. Bonnevalle N, Mansat P, Mansat M, Bonnevalle P: Hemiarthroplasty for osteoarthritis in shoulder with dysplastic morphology. *J Shoulder Elbow Surg* 2011;20(3):378-384.